

Superior Canal Dehiscence Syndrome

Abdulrahman A. Hagr, MBBS, FRCS(C)

*Department of Otolaryngology
Faculty of Medicine, King Saud University
Riyadh, Saudi Arabia
dhagr90@yahoo.com*

Abstract. Superior canal dehiscence syndrome, or Minor's syndrome, is a recently described disease that results from the absence of bone over the superior semicircular canal which results in the communication between the perilymphatic space of the canal and the intra-cranial space. It is characterized by a wide range of symptoms involving imbalance, hearing loss or both. Symptoms may include strange perceptions such as being able to hear one's eyes moving, and dizziness on exposure to loud sounds. Because of this, patients may undergo multiple investigations, inappropriate treatments including psychiatric interventions, or even inappropriate surgical interventions. Superior canal dehiscence syndrome is not a rare disease, thus is relatively easy to diagnose. Current treatment approaches include reassurance, and in a few patients, surgical intervention. Its diagnosis requires a high index of suspicion, since it is a new syndrome and many family doctors, neurologists and even otolaryngologists are not aware of its existence. Its diagnosis can be challenging, since it can be easily confused with other conditions. Its symptoms mimic many other better known conditions. The literature has been reviewed to characterize this syndrome's presentations, investigations and treatments. Hopefully this will increase the awareness of the medical community about this complex and interesting disease.

Keywords: Superior semicircular canal, Dehiscence and Ear.

Correspondence & reprint request to:

Dr. Abdulrahman Hagr

P.O. Box 245, Riyadh 11411, Saudi Arabia

Accepted for publication: 20 March 2010. Received: 17 January 2010.

Introduction

Balance is a complex function which receives input from three major organs, the vestibular system of the inner ear, the eyes and peripheral proprioception. The brain centers analyze and monitor these inputs as well as control the output of balance programs on the body posture, movement and vision. One of the movements detected by the inner ear is angular acceleration (*i.e.*, turning movements), sensed by the semicircular canals. There are six semicircular canals, three on each side, and all three semicircular canals are arranged in orthogonal planes in each ear. Therefore, they are well placed to detect angular acceleration in any plane of head movements.

Superior canal dehiscence syndrome (SCD) is a recently described disease that results from the absence of bone over the superior semicircular canal, and is characterized by a wide range of vestibular and auditory presentations, or a combination of both. It was first reported by Minor in 1998^[1]. Since then, this abnormality has been detected and described in several additional reports. The common symptoms of this disease include Tulio's phenomenon or Hennebert's sign (nystagmus induced by loud noises or by pressure in the auditory canal, respectively). Nystagmus aligned with the plane of the SCC can also be elicited by straining or Valsalva maneuver. The variability of presenting symptoms of SCD makes it difficult for clinicians to recognize without a high index of suspicion, since some patients present with predominantly auditory symptoms, others with predominantly vestibular symptoms, and there is variable severity. This is why many patients have received wrong diagnoses such as Meniere's disease, perilymph fistula, migraine, otosclerosis and patulous Eustachian tube. Some have undergone negative middle ear exploration, whereas in some, stapedectomy, perilymphatic fistula repair or tympanoplasty I has been mistakenly performed without any benefit^[2-4]. Moreover, because of somewhat "bizarre" associated symptoms, such as ability to hear one's footsteps and eye movements, some patients end up in psychiatry clinics. However, with a careful taken history, physical examination and CT scan work-up as well as a high degree of suspicion, SCD can be easily differentiated from other inner ear disorders^[5].

This new entity is not rare; Carey *et al.*^[6] found up to 0.7% of individuals may have absence of the bone over the superior semicircular

canal on the basis of temporal bone survey. Some authors have hypothesized a congenital malformation of the skull base as the underlying cause for this disease^[6-7]. In medical treatment, often used vestibular pharmacotherapy (*e.g.*, betahistine hydrochloride, vestibular suppressants and antihistamines) has been rarely prescribed since there was no pathophysiological rationale for these agents to be effective. In more extreme circumstances, patients with intractable symptoms may require or seek surgical treatment. The aim of the present paper is to review the current state of knowledge about SCD and to provide an overview of the subject.

Methods

Materials, Methods and Results

An extensive search of the literature was performed in Medline and other available database sources, using the keywords “Superior”, “canal”, “dehiscence”, “syndrome”, “dizziness”, and “imbalance”. The keyword “superior canal dehiscence” was considered primary and was either used individually, or combined with each of the other keywords. The PubMed database was our major search tool, which was evaluated from 1966 to June 2009 to identify publications on SCD as well as information from electronic links. In addition, related books were reviewed, and reference lists from the retrieved articles were manually searched.

Study selection included all types of article (Meta analysis, prospective, retrospective, reviews, case-reports, *etc...*). Those studies which exclusively included patients with dehiscence of the posterior or horizontal canal were excluded. Literature reviews of pooled data were performed. The PubMed search yielded 170 publications since March 1998 until March of 2009. The heterogeneous nature of the disease was reflected in the non-homogeneous studies. This made it difficult to summarize the results, and severely limits pooled statistical analysis, hence this was not presented.

Discussion

The exact incidence of symptomatic superior semicircular canal dehiscence is unknown. However, some temporal bones dissection studies have proposed a prevalence of 0.5%^[6,8]. It seems there was a male and left-side predominance^[3,4,9,10].

Etiology

The etiology of SCD is not well known. The origin of SCD could be either developmental^[6,7,11,12] or congenital^[13-16], although, a genetic substrate has been proposed in some cases^[4,17,18]. In 2000, Carey *et al.*^[6] proposed that SCD was a failure of adequate bone formation over the superior canal after they demonstrated uniformly thin bone over the SSC with progressive thickening until 3 years of age. Thus, SCD may be the result of progressive thinning of an inadequately formed bone due to erosion from intracranial cerebrospinal fluid pressure or the brain mass. The progenitor phase could be present in childhood and manifest clinically later in adulthood. This proposal has been accepted by many authors. Moreover, SCD has been reported in children^[19,20].

Interestingly, Friedland and Michel^[21] reported two patients with failure of SCD resurfacing because of bone resorption. They demonstrated significantly reduced values of the cross-sectional area of the middle fossa craniotomy in these two SCD patients as compared with normal controls using high resolution CT scans. They suggested that there may be factors beyond the anatomy of the petrous pyramid which contribute to the development of a dehiscence. However, supporting the developmental theory is the fact that the superior canal is the first canal to develop and to become ossified, followed by the posterior and then the horizontal canal^[22,23]. Therefore, an ossification arrest in the semicircular canals does not fully explain the manifestations of dehiscence preferentially in the SSC, since the posterior and horizontal canals should be more severely affected by ossification arrest due to their later development.

Pathophysiology

Head rotation causes relative movement of the endolymph in the semicircular canal which bends the cupula; the embedded hairs of the hair cells; and causes stimulation of the relevant vestibular nerve. The main sense organ in each canal is located in the abutted end of the canal, and is called the crista. This contains neural sensors which are stimulated by mechanical movements of the cupula. Normal stimuli for copular movement are rotational acceleration of the head in the plane of the canal.

The mechanisms causing both the auditory and vestibular features of this disease are still under discussion. However, the mobile “third window” theory is the most accepted explanation. In this concept, the existence of a dehiscence at the apical turn of the SSC (in addition to the normally present oval and round windows of the inner ear) leads to transmission of the pressure changes in the intracranial cavity or middle ear to the inner ear, and vice versa. This leads to altered neural firing rates in the vestibular system, and may also alter inner ear fluid dynamics causing dissipation of acoustic energy^[3,21].

To explain the auditory or acoustic induced symptoms, essentially, stapes movements normally would cause pressure in the scala tympani. This would be transmitted across the basilar membrane to be relieved at the round window membrane. With the third window in the SCD connected to the scala vestibuli, stapes movement induced perilymph pressure was instead channeled through this low impedance pathway. This results in pressure release through the third window, with less energy expended in moving the basilar membrane. This fluid flow also results in the movement of the SCC cupula, and in an inappropriate stimulation of the rotation sensing vestibular structure (the SCC) by this acoustic energy. Therefore, the third mobile window shunting of acoustic energy to the SCC results in the vertical–torsional eye movement that aligned with the plane of the affected canal, Ewald’s first law^[24]. In addition, Valsalva against pinched nostrils (forcing air into the middle ear through the Eustachian tube) and positive pressure changes in the EAC (which causes ampullofugal deflection (excitatory) of the cupula) increases the discharge rates of the vestibular nerve. The normal vestibule-ocular reflex mediated eye movements will be vertical–torsional, with nystagmus slow-phase components directed upward and torsioning away from the affected ear^[2,14,24]. The converse was observed in cases of negative pressure changes in the EAC, such as Valsalva against a closed glottis which increases intracranial pressure^[2,17,25]. Sneezing and cough may increase the middle ear pressure and causes the outward bulging of membranous labyrinth in the bone dehiscence area of the superior canal; similar to positive pressure changes in the EAC. However, both may also increase the intracranial pressure and causes the inward bulging of the membranous labyrinth; similar to negative pressure changes in the EAC.

Although, there was no clear correlation between symptoms and the size of SCD^[13]. The third window explains the vestibular manifestations of SCD, which included chronic dizziness which gets worse in the presence of loud noises, Tullio's phenomenon (eye movements and vertigo induced by loud noise) and Hennebert's sign (eye movements and vertigo induced by pressure in the external auditory canal). Plus, change of atmospheric pressure, coughing, playing wind instruments, sneezing, straining or heavy lifting; even drop attacks has been reported with SCD^[26].

Vestibular symptoms are presenting as the most common and are the most debilitating complaints^[1,14,27]. However, patients can also present with auditory symptoms, with or without vestibular symptoms^[1,3,4]. The dehiscence may act as a shunt for air-conducted sound; leads to reduce the fluid-displacement wave to the cochlear partition; reducing the stimulus that activates the hearing mechanism through air conduction hearing. On the other hand, bone-conduction includes the summation of multiple stimulus pathways, and most are improved by SCD, such that it results in improved bone conduction hearing^[28]. Hence, classically, SCD induces a decrease in the sensitivity of air-conduction at low-frequency and an increase in the sensitivity of bone conduction at low-frequency, simultaneously (< 2 kHz)^[2,14]. The combination of these two alterations in sensitivity can result in a significant air–bone gap (this explains the “pseudo-conductive” hearing loss where). Moreover, patient's increased sensitivity to bone conducted sounds, and brain pulsations through the dehiscence results in hyperacusis to body sounds. This includes autophony, being able to hear their heartbeat; hearing heel strikes with the ground when stepping; eye movements and hearing joint articulation sounds. Used diagnostically, some patients can hear a tuning fork applied on their elbow or ankle. The bone conduction enhancement results in the Weber test with a 256 or 512 Hz tuning fork lateralizing to the affected ear. This can be used as a screening test in the absence of conductive hearing loss, unless the patient has bilateral SCD. Interestingly, these auditory symptoms have been historically attributed to “inner ear conductive hearing loss”^[29,30].

It has not been elucidated why some patients suffer from hearing disturbance, few others from dizziness, others from both kinds of symptoms, while some remain asymptomatic^[31]. However, factors that may contribute to the differences in the auditory, and/or vestibular

manifestations of superior canal dehiscence include whether or not the cochlear aqueduct is patent, and the relative compliance of the round window membrane^[14].

Audiology

Hearing loss may be the only symptom of superior canal dehiscence syndrome (SCD)^[3,4,13]. An air-bone gap with an intact tympanic membrane typically represents a disruption of the middle-ear conduction, with etiologies which include congenital ossicular malformations, otosclerosis, ossicular chain fixation or discontinuity. Audiogram, impedance, OAE and ENG testing are useful as an agent for diagnosis.

As mentioned above, studies have shown that a third window could elevate air-conduction thresholds, and a decrease or not affect bone-conduction thresholds^[3,28,32]. When conductive hearing loss is seen in SCD, it tends to be predominantly in the low frequencies^[5]. This air-bone gap may be present with air conduction thresholds in the normal range^[3,9] (*i.e.*, less than 20 dB HL), and with the bone conduction thresholds at reported has being 0 dB HL. Many audiologists will not test negative thresholds for bone conduction; a common practice being to stop if responses are present at 0 dB HL. Often, SCD patients will have bone conduction thresholds at -5 or - 10 dB HL. Therefore, the physician may have to specifically request testing for negative bone conduction threshold testing in suspicious cases with a mild air bone gap in the low frequencies.

The presence of acoustic reflex in an ear with conductive hearing loss, provides a useful screening test in the identification of patients in which the conductive hearing loss on the audiometry may be due to superior canal dehiscence, rather than to a middle ear problem. Most middle ear conditions will result in the loss of the acoustic reflex^[2]. Otoacoustic emission (OAE) may also be present despite a conductive hearing loss, at least in the higher frequencies. Again, most middle ear pathologies causing conductive hearing loss also abolish OAEs. Electrooculography (EOG) can record abnormal nystagmus elicited with loud sounds, fistula testing, or by Valsalva. These investigations can be useful when patient's symptoms or signs are multifaceted or are uncharacteristic, which is not unusual with SCD.

Superior canal dehiscence syndrome may lower the thresholds for vestibular evoked myogenic potential (VEMP) in the affected ear^[9,27,33]. This VEMP test is a large and short latency inhibitory potential in the tonically contracted ipsilateral sternocleidomastoid muscle. In response to a brief loud sound, usually short broadband clicks or tone-bursts delivered *via* headphones. The response is recorded electromyographically using surface electrodes over the ipsilateral sternocleidomastoid muscle. Thus, it represents one vestibule-spinal reflex whose afferent limb arises from the saccule and not from the cochlea. Therefore, it depends upon both sound transmission through the middle ear and structural integrity of the otolith organ, including the superior semicircular canal. In SCD syndrome, there is a 'path of at least resistance' that shunts acoustic energy through the vestibular labyrinth rather than through the cochlea. This typically yields a 20 dB lowered VEMP threshold (70 dB compared with 95 dB). Nevertheless, it gives great value to VEMP in supporting the diagnosis of SCD^[3,4,27,34] and makes it useful and cost-effective screening test for SCD^[10,14]. Moreover, VEMP thresholds are concordant with symptoms, therefore helping in the differential diagnosis in selecting the most affected ear for surgery; in cases of bilaterally SCD^[35] and confirming the outcome of surgical repair^[17,35].

CT Scan

The diagnosis of SCD can be a clinical challenge, since patients with SCD can present with various vestibular and/or auditory symptoms. Plus it may mimics other otologic entities, for example, otosclerosis, patulous Eustachian tube and Meniere's disease^[26,36-38]. Therefore, the diagnosis of superior canal dehiscence syndrome depends on careful correlation of patient's history, physical examination and investigation including imaging with high resolution computed tomography (CT) scan of the temporal bones. This is the gold standard to detect the dehiscence of bone overlying in the superior canal, and the diagnosis depends strongly on this (Fig. 1)^[39,40]. However, CT scan interpretation will depends on many other factors such as radiologist experience, size of fistula, CT scan thickness, as well as direct or reformatted plane techniques. With expert evaluation, the CT scan can have a specificity of 99% and a positive predictive value of 93% in the detection of symptomatic SCD syndrome^[39]. Other authors recommend CT-scanning only to confirm a

strong clinical suspicion and not as a tool to screen for SCD, because of a low positive–predictive value with a range of 57–67%^[41]. It has also been proposed that patient who have had stapedectomy without change in postoperative conductive deficit despite uncomplicated surgery,^[5] may also justify imaging. Some would consider it for any patient with isolated conductive or mixed hearing loss with a normal ear drum before operation^[13].

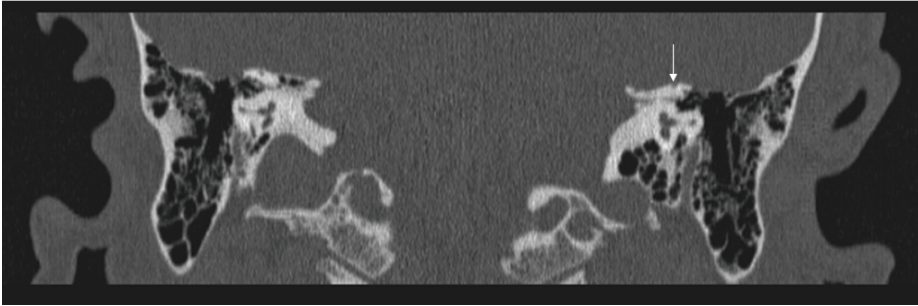


Fig. 1. A 0.5-mm Coronal CT scan through the left temporal bone demonstrates dehiscence of bone (arrow) over the left superior canal in 38-year-old male with sound (Tullio phenomenon) and pressure induced (Hennebert's sign) vertigo associated with dehiscence of the arcuate eminence (roof) of the superior semicircular canal.

The prevalence of SCD in standard CT scan imaging is about 10%^[6,41,42]. This figure may be halved by reconstructing the images in the plane of the canal^[41]. However, radiographic dehiscence of the SSC still significantly exceeds the histologic prevalence of 0.5%^[6]. Therefore, the SCD on imaging examinations can be an imaging artifact, and is often an asymptomatic and incidental finding^[5]. Thus, careful evaluation of many cuts is critical since SCD can be seen as one single cut only in the CT scan. Thus, it can be a false positive, due to technical issues such as partial volume averaging effect^[14,39,43,44], or just blue lining of the canal with the bone still covering it, and that may not need surgical intervention^[41]. Hillman *et al.*^[5] insist on 2 consecutive cuts of 1 mm thickness that show dehiscence as a diagnostic criterion. Otherwise, using an ultrahigh-resolution helical CT scan with 0.5-mm collimation plus reconstructions in the plane of the superior canal and orthogonal to it. These are ideal for the identification of SCD, as proposed by Belden *et al.*^[39]. Later, Hillman *et al.*^[5] reported a CT scan protocol that gives excellent bony detail - 1 mm per section; non-contrast coronal cuts with a

window width/ level setting of 4000/450-. Although, Minor^[2] alternatively proposed ultra-high resolution CT scanning (0.5 mm cuts) that may also be used to provide better specificity.

Virtual endoscopy (computer processing of 3-D image datasets) is a new way to confirm SCD. Wang *et al.*^[45] did a pilot study on three definite SCD subjects; two possible SCD subjects, and five control subjects to examine the threshold of virtual endoscopy in diagnosing SCD. They reported significant thresholds differed between affected ear compare to the unaffected ears. Furthermore, normal controls base on two radiologists blinded to clinical history and independently reviewed the virtual endoscopy images twice, separated by 3 months.

MRI is also an excellent tool to diagnose SCD where T2 weighted and fast spin echo can show the clear contact between inner ear and brain fluid^[6]. MRI may have as much as 96% sensitivity and 98% specificity for the identification of the syndrome^[46]. Since MRI is still expensive, time consuming and inconvenient for many patients. It may be appropriate for patients with pure vestibular symptoms to exclude retrocochlear lesion, or before performing surgical intervention. In rare cases, MRI may shows the underlining cause of symptoms as being SCD when performed for suspected intracranial lesions^[47].

Surgery

In the majority of cases with SCD have mild symptoms and do not require surgery. Avoidance of the precipitating stimuli can be quite effective in managing the condition^[17,48]. Surgical repair of the effective canal may be considered as a valid therapeutic option; in cases with debilitating symptoms such as frequent or permanent disequilibrium; unsteadiness or other incapacitating vestibular or auditory symptoms. Other underlining cause of symptoms like benign positional vertigo BPPV^[5] should be treated before considering surgery.

Surgical repair can be performed by accessing the dehiscence through a middle fossa or transmastoid approach. The transmastoid approach is attractive since it is less invasive and requires no temporal lobe retraction^[43,49]. Furthermore, there is no manipulation of the dehiscence, if plugging is anticipated^[43] and is more familiar to otologists^[50]. It can even be performed under local anesthesia^[49]. Moreover, the mastoid cortical bone graft is thicker and less likely to get reabsorbed, plus the

stability is substantially better than outer table temporal bone^[50]. After identifying the area of dehiscence, resurfacing with calvarial bone grafts and temporalis fascia can be done. An alternative way is to plug the canal with fascia, bone pate or hydroxyapatite bone cement. Vlastarakos *et al.*^[51] performed a meta- analysis and reported success rates. Thus, in favor of canal plugging and canal capping over resurfacing of the SSC. It is worth mentioning that a tympanostomy tube may be beneficial in some patients with symptoms induced by pressure in the external auditory canal^[14,52].

Summary

SCD syndrome is a variant of perilymph fistula and was described by Minor *et al.* in 1998. It is clinically characterized by attacks of vertigo and oscillopsia, induced by loud sound (Tullio's phenomenon); pressure changes in the external ear canal (Hennebert's sign) or Valsalva maneuvers. The creation of a third mobile window in the bony labyrinth, in addition to the normal round and oval windows, it allows for intracranial contact with the inner ear fluid. Plus, it altered perilymph and endolymph dynamics making the auditory and vestibular apparatus sensitive to sound or pressure stimuli. Delay of diagnosis is frequently seen because of low awareness of this disease. Moreover, misdiagnosis could occur since the signs and symptoms of this syndrome can be quite variable, and resemble more common conditions such as Meniere's disease, benign paroxysmal positional vertigo, otosclerosis or Eustachian tube dysfunction.

Audiometry can demonstrate negative bone conduction hearing thresholds, with apparent air-bone gaps. The preservation of stapedial reflexes, OAE and reduced thresholds in VEMP indicates that neither the tympanic membrane nor middle ear is the cause of the conductive loss. Diagnosis requires a high index of suspicion, because of the multiple symptoms that overlap with other disease entities. The decision to undergo surgery for SCD requires careful consideration of symptoms' severity and ability to tolerate these symptoms relative to the risks of the surgery. Finally, the author suggests that more education and awareness of this disease as well as further research in this field with large study group and long-term follow up of patients is highly recommended.

Acknowledgments

The author is grateful for the support of Research Chair for Hearing Disability and Implantable Devices, and would like to acknowledge the assistance of his mentor, Professor Manohar Bance, in the editing of this manuscript.

References

- [1] **Minor LB, Solomon D, Zinreich JS, Zee DS.** Sound- and/or pressure-induced vertigo due to bone dehiscence of the superior semicircular canal. *Arch Otolaryngol Head Neck Surg* 1998; **124**(3): 249-258.
- [2] **Minor LB.** Superior canal dehiscence syndrome. *Am J Otol* 2000; **21**(1): 9-19.
- [3] **Minor LB, Carey JP, Cremer PD, Lustig LR, Streubel SO, Ruckenstein MJ.** Dehiscence of bone overlying the superior canal as a cause of apparent conductive hearing loss. *Otol Neurotol* 2003; **24**(2): 270-278.
- [4] **Mikulec AA, McKenna MJ, Ramsey MJ, Rosowski JJ, Herrmann BS, Rauch SD, Curtin HD, Merchant SN.** Superior semicircular canal dehiscence presenting as conductive hearing loss without vertigo. *Otol Neurotol* 2004; **25**(2): 121-129.
- [5] **Hillman TA, Kertesz TR, Hadley K, Shelton C.** Reversible peripheral vestibulopathy: the treatment of superior canal dehiscence. *Otolaryngol Head Neck Surg* 2006; **134**(3): 431-436.
- [6] **Carey JP, Minor LB, Nager GT.** Dehiscence or thinning of bone overlying the superior semicircular canal in a temporal bone survey. *Arch Otolaryngol Head Neck Surg* 2000; **126**(2): 137-147.
- [7] **Hirvonen TP, Weg N, Zinreich SJ, Minor LB.** High-resolution CT findings suggest a developmental abnormality underlying superior canal dehiscence syndrome. *Acta Otolaryngol* 2003; **123**(4): 477-481.
- [8] **Crovetto M, Whyte J, Rodriguez OM, Lecumberri I, Martinez C, Eléxpuru J.** Anatomic-radiological study of the Superior Semicircular Canal Dehiscence Radiological considerations of Superior and Posterior Semicircular Canals. *Eur J Radiol* 2009.
- [9] **Streubel SO, Cremer PD, Carey JP, Weg N, Minor LB.** Vestibular-evoked myogenic potentials in the diagnosis of superior canal dehiscence syndrome. *Acta Otolaryngol Suppl* 2001; **545**: 41-49.
- [10] **Zhou G, Gopen Q, Poe DS.** Clinical and diagnostic characterization of canal dehiscence syndrome: a great otologic mimicker. *Otol Neurotol* 2007; **28**(7): 920-926.
- [11] **Chen EY, Paladin A, Phillips G, Raske M, Vega L, Peterson D, Sie KC.** Semicircular canal dehiscence in the pediatric population. *Int J Pediatr Otorhinolaryngol* 2009; **73**(2): 321-327.
- [12] **Tsunoda A, Terasaki O.** Dehiscence of the bony roof of the superior semicircular canal in the middle cranial fossa. *J Laryngol Otol* 2002; **116**(7): 514-518.
- [13] **Martin C, Chahine P, Veyret C, Richard C, Prades JM, Pouget JF.** Prospective radiological study concerning a series of patients suffering from conductive or mixed hearing loss due to superior semicircular canal dehiscence. *Eur Arch Otorhinolaryngol* 2009; **266**(8): 1175-1181.

- [14] **Minor LB.** Clinical manifestations of superior semicircular canal dehiscence. *Laryngoscope* 2005; **115**(10): 1717-1727.
- [15] **Potyagaylo VL, Della Santina CC, Minor LB, Carey JP.** Superior canal dehiscence is not due to cephalic displacement of the labyrinth. *Ann N Y Acad Sci* 2005; **1039**: 498-502.
- [16] **Crovetto de la Torre MA, Whyte OJ, Cisneros Gimeno AI, Basurko Aboitz JM, Oleaga ZL, Sarrat TR.** Superior semicircular canal dehiscence syndrome. Embryological and surgical consideration. *Acta Otorrinolaringol Esp* 2005; **56**(1): 6-11.
- [17] **Brantberg K, Bergenius J, Mendel L, Witt H, Tribukait A, Ygge J.** Symptoms, findings and treatment in patients with dehiscence of the superior semicircular canal. *Acta Otolaryngol* 2001; **121**(1): 68-75.
- [18] **Hildebrand MS, Tack D, Deluca A, Hur IA, Van Rybroek JM, McMordie SJ, Muilenburg A, Hoskinson DP, Van Camp G, Pensak ML, Storper IS, Huygen PL, Casavant TL, Smith RJ.** Mutation in the COCH gene is associated with superior semicircular canal dehiscence. *Am J Med Genet A* 2009; **149A**(2): 280-285.
- [19] **Modugno G, Brandolini C, Savastio G, Ceroni AR, Pirodda A.** Superior semicircular canal dehiscence: a series of 13 cases. *ORL J Otorhinolaryngol Relat Spec* 2005; **67**(3): 180-184.
- [20] **Zhou G, Ohlms L, Liberman J, Amin M.** Superior semicircular canal dehiscence in a young child: implication of developmental defect. *Int J Pediatr Otorhinolaryngol* 2007; **71**(12): 1925-1928.
- [21] **Friedland DR, Michel MA.** Cranial thickness in superior canal dehiscence syndrome: implications for canal resurfacing surgery. *Otol Neurotol* 2006; **27**(3): 346-354.
- [22] **Nemzek WR, Brodie HA, Chong BW, Babcock CJ, Hecht ST, Salamat S, Ellis WG, Seibert JA.** Imaging findings of the developing temporal bone in fetal specimens. *AJNR Am J Neuroradiol* 1996; **17**(8): 1467-1477.
- [23] **Satar B, Mukherji SK, Telian SA.** Congenital aplasia of the semicircular canals. *Otol Neurotol* 2003; **24**(3): 437-446.
- [24] **Cremer PD, Minor LB, Carey JP, Della Santina CC.** Eye movements in patients with superior canal dehiscence syndrome align with the abnormal canal. *Neurology* 2000; **55**(12): 1833-1841.
- [25] **Watters KF, Rosowski JJ, Sauter T, Lee DJ.** Superior semicircular canal dehiscence presenting as postpartum vertigo. *Otol Neurotol* 2006; **27**(6): 756-768.
- [26] **Brantberg K, Ishiyama A, Baloh RW.** Drop attacks secondary to superior canal dehiscence syndrome. *Neurology* 2005; **64**(12): 2126-2128.
- [27] **Brantberg K, Bergenius J, Tribukait A.** Vestibular-evoked myogenic potentials in patients with dehiscence of the superior semicircular canal. *Acta Otolaryngol* 1999; **119**(6): 633-640.
- [28] **Rosowski JJ, Songer JE, Nakajima HH, Brinsko KM, Merchant SN.** Clinical, experimental, and theoretical investigations of the effect of superior semicircular canal dehiscence on hearing mechanisms. *Otol Neurotol* 2004; **25**(3): 323-332.
- [29] **House JW, Sheehy JL, Antunez JC.** Stapedectomy in children. *Laryngoscope* 1980; **90**(11 Pt 1): 1804-1809.
- [30] **Bess FH, Miller GW, Glasscock ME, III, Bratt GW.** Unexplained conductive hearing loss. *South Med J* 1980; **73**(3): 335-338.
- [31] **Mikulec AA, Poe DS, McKenna MJ.** Operative management of superior semicircular canal dehiscence. *Laryngoscope* 2005; **115**(3): 501-507.

- [32] **Preis M, Attias J, Hadar T, Nageris BI.** Cochlear third window in the scala vestibuli: an animal model. *Otol Neurotol* 2009.
- [33] **Watson SR, Halmagyi GM, Colebatch JG.** Vestibular hypersensitivity to sound (Tullio's phenomenon): structural and functional assessment. *Neurology* 2000; **54**(3): 722-728.
- [34] **Ostrowski VB, Byskosh A, Hain TC.** Tullio phenomenon with dehiscence of the superior semicircular canal. *Otol Neurotol* 2001; **22**(1): 61-65.
- [35] **Welgampola MS, Myrie OA, Minor LB, Carey JP.** Vestibular-evoked myogenic potential thresholds normalize on plugging superior canal dehiscence. *Neurology* 2008; **70**(6): 464-472.
- [36] **Poe DS.** Diagnosis and management of the patulous eustachian tube. *Otol Neurotol* 2007; **28**(5): 668-677.
- [37] **Halmagyi GM, Aw ST, McGarvie LA, Todd MJ, Bradshaw A, Yavor RA, Fagan PA.** Superior semicircular canal dehiscence simulating otosclerosis. *J Laryngol Otol* 2003; **117**(7): 553-557.
- [38] **Merchant SN, Rosowski JJ, McKenna MJ.** Superior semicircular canal dehiscence mimicking otosclerotic hearing loss. *Adv Otorhinolaryngol* 2007; **65**: 137-145.
- [39] **Belden CJ, Weg N, Minor LB, Zinreich SJ.** CT evaluation of bone dehiscence of the superior semicircular canal as a cause of sound- and/or pressure-induced vertigo. *Radiology* 2003; **226**(2): 337-343.
- [40] **Banerjee A, Whyte A, Atlas MD.** Superior canal dehiscence: review of a new condition. *Clin Otolaryngol* 2005; **30**(1): 9-15.
- [41] **Cloutier JF, Belair M, Saliba I.** Superior semicircular canal dehiscence: positive predictive value of high-resolution CT scanning. *Eur Arch Otorhinolaryngol* 2008; **265**(12):1455-1460.
- [42] **Williamson RA, Vrabec JT, Coker NJ, Sandlin M.** Coronal computed tomography prevalence of superior semicircular canal dehiscence. *Otolaryngol Head Neck Surg* 2003; **129**(5): 481-489.
- [43] **Agrawal SK, Parnes LS.** Transmastoid superior semicircular canal occlusion. *Otol Neurotol* 2008; **29**(3): 363-367.
- [44] **Williamson RA, Vrabec JT, Coker NJ, Sandlin M.** Coronal computed tomography prevalence of superior semicircular canal dehiscence. *Otolaryngol Head Neck Surg* 2003; **129**(5): 481-489.
- [45] **Wang WH, Lin YC, Weng HH, Chen WC.** Detection of superior semicircular canal dehiscence by virtual endoscopy: a pilot study. *Otolaryngol Head Neck Surg* 2008; **139**(5): 624-629.
- [46] **Krombach GA, Schmitz-Rode T, Haage P, DiMartino E, Prescher A, Kinzel S, Günther RW.** Semicircular canal dehiscence: comparison of T2-weighted turbo spin-echo MRI and CT. *Neuroradiol* 2004; **46**(4): 326-331.
- [47] **Crane BT, Carey JP, McMenomey S, Minor LB.** Meningioma Causing Superior Canal Dehiscence Syndrome. *Otol Neurotol* 2009.
- [48] **Carey JP, Migliaccio AA, Minor LB.** Semicircular canal function before and after surgery for superior canal dehiscence. *Otol Neurotol* 2007; **28**(3): 356-364.
- [49] **Kirtane MV, Sharma A, Satwalekar D.** Transmastoid repair of superior semicircular canal dehiscence. *J Laryngol Otol* 2009; **123**(3): 356-358.
- [50] **Crovetto M, Areitio E, Elexpuru J, Aguayo F.** Transmastoid approach for resurfacing of Superior Semicircular Canal dehiscence. *Auris Nasus Larynx* 2008; **35**(2): 247-249.

- [51] **Vlastarakos PV, Proikas K, Tavoulari E, Kikidis D, Maragoudakis P, Nikolopoulos TP.** Efficacy assessment and complications of surgical management for superior semicircular canal dehiscence: a meta-analysis of published interventional studies. *Eur Arch Otorhinolaryngol* 2009; **266**(2): 177-186.
- [52] **Minor LB.** Labyrinthine fistulae: pathobiology and management. *Curr Opin Otolaryngol Head Neck Surg* 2003; **11**(5): 340-346.

متلازمة انكشاف القناة الهلالية العلوية

عبدالرحمن عبدالله حجر

قسم الأنف والأذن والحنجرة ، كلية الطب ، جامعة الملك سعود
الرياض - المملكة العربية السعودية

المستخلص. متلازمة انكشاف القناة الهلالية العلوية أو متلازمة ماينر هي مرض وصف في الآونة الأخيرة، والذي ينتج عن عدم وجود العظم المغطي للقناة الهلالية العلوية مما يؤدي إلى اتصال الوعاء اللمفي بجوف القحف. يتميز هذا المرض بطيف واسع من الأعراض التي تتطوي على اختلال التوازن أو فقدان السمع أو كليهما. يمكن أن تشمل الأعراض تصورات غريبة مثل قدرة المصاب على سماع حركة العيون، والدوار عند التعرض لأصوات صاخبة. لهذا، قد يخضع المرضى لاستقصاءات متعددة، بما في ذلك التدخلات غير الملائمة أو العلاجات النفسية، أو حتى التدخلات الجراحية غير المناسبة. متلازمة انكشاف القناة الهلالية العلوية ليست مرضاً نادراً وهي سهلة التشخيص نسبياً. النهج المتداول في معالجة هذه الحالة يشمل التطمين، وعدد قليل من المرضى يحتاج للتدخل الجراحي، لأنها متلازمة جديدة والعديد من أطباء الأسرة، والأعصاب والأذن لا يعرفون شيئاً عن وجودها، لهذا يتطلب التشخيص ارتفاع حس الاشتباه. قد يكون تشخيص هذه المتلازمة أمراً صعباً، حيث من السهل الالتباس بأمراض أخرى، كما أن أعراضها تشبه العديد من الأمراض المعروفة بشكل أفضل. لقد قمنا بمراجعة ما نشر لنحدد ما يميز هذه المتلازمة من أعراض واستقصاءات وعلاج. كما نأمل أن يزيد هذا من وعي المجتمع الطبي حول هذا المرض المعقد والمثير للاهتمام.